

## EPIZOOTIOLOGIC STUDIES OF AVIAN VACUOLAR MEYLINOPATHY IN WATERBIRDS

Tonie E. Rocke,<sup>1,3</sup> Nancy J. Thomas,<sup>1</sup> Tom Augspurger,<sup>2</sup> and Kimberli Miller<sup>1</sup>

<sup>1</sup> US Geological Survey, National Wildlife Health Center, 6006 Schroeder Rd., Madison, Wisconsin, 53711, USA

<sup>2</sup> US Fish and Wildlife Service, P.O. Box 33726, Raleigh, North Carolina 27636, USA

<sup>3</sup> Corresponding author (email: tonie\_rocke@usgs.gov)

**ABSTRACT:** Epizootic avian vacuolar myelinopathy (AVM) was first recognized as a neurologic disease in bald eagles (*Haliaeetus leucocephalus*) and American coots (*Fulica americana*) in Arkansas, USA in 1994 and 1996, respectively, but attempts to identify the etiology of the disease have been unsuccessful to date. Between 1998 and 2001, wing clipped sentinel birds (wild American coots and game farm mallards [*Anas platyrhynchos*]) were released at Lake Surf, North Carolina, a lake with recurrent outbreaks of AVM, in order to gain a better understanding of the epizootiology of the disease. As early as 5–7 days post-release, sentinel coots and mallards showed neurologic signs of disease and were confirmed with AVM upon histologic examination of their brains. Serial releases of sentinel mallards during the summer, fall, and winter of 2000–01 demonstrated that exposure to the causative agent at a threshold sufficient to manifest disease was seasonal and occurred over about a 2 mo period, during November and December. Our findings that disease onset can be very rapid (5–7 days) and that exposure to the causative agent of AVM is site-specific, seasonal (late fall to early winter), and occurs over a relatively short duration (several months) supports the hypothesis that the disease is caused by a chemical substance, most likely of natural origin.

**Key words:** American coots, avian vacuolar myelinopathy, mallards, sentinels.

### INTRODUCTION

During the winter of 1994–95, a neurologic disease, described as avian vacuolar myelinopathy (AVM) (Thomas et al., 1998), killed 29 bald eagles (*Haliaeetus leucocephalus*) at DeGray Lake in southwestern Arkansas (USA). In 1996, the disease was also recognized in American coots (*Fulica americana*) at DeGray lake and coots and/or bald eagles at two other lakes (Lake Ouachita and Lake Hamilton) in Arkansas. Clinical signs in affected birds included impaired flight or inability to fly, incoordination, and abnormal posture. Sick birds were alert and aware of their surroundings, but all of the moribund bald eagles ultimately died. At least 58 bald eagles died from AVM in the three Arkansas lakes from 1994–98, and an undetermined number of coots were affected. Upon necropsy, affected birds were generally in good body condition and many had green fluid in the stomach. The only consistent abnormality noted upon histologic examination of tissues from affected coots and eagles was diffuse, spongy degeneration of

the white matter of the central nervous system (Thomas et al., 1998).

Since 1994, outbreaks of AVM have been confirmed in coots at a total of 10 lakes in Arkansas, North Carolina, South Carolina, and Georgia, USA. Additional bald eagles have died from AVM in North and South Carolina, and the disease has also been diagnosed in several species of waterfowl, including mallards (*Anas platyrhynchos*), ring-necked ducks (*Aythya collaris*), and buffleheads (*Bucephala albeola*; Augspurger, unpubl. data), although the numbers of afflicted waterfowl observed were much fewer than coots. Outbreaks confirmed to date have occurred during the winter months, as early as November, and affected birds were observed into the following spring, as late as March or April. All the lakes where AVM-affected birds have been found are wintering sites for migratory populations and are man-made reservoirs, but they vary in age, size, depth, surrounding natural habitat, and land use practices.

Unfortunately, the cause of AVM has not been identified, despite extensive di-

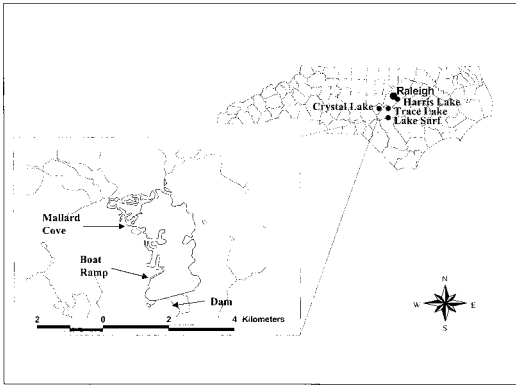


FIGURE 1. Map of North Carolina showing the location of four lakes where sentinel birds were released and a detailed map of Lake Surf showing the location of sentinel release sites during the 2000–01 season.

agnostic testing by multiple investigators. The neurologic lesion in affected birds is suggestive of a toxic process, but toxic concentrations of chemicals, of either natural (viz., biotoxin) or man-made (viz., xenobiotic) origin, have not been detected in the tissues from affected birds (Thomas et al., 1998). Because outbreaks of the disease coincide with migration of coots, it was unclear if birds acquired the disease at the location where sick and dead birds were found or if birds were exposed to the causative agent elsewhere. The objectives of our study were to determine the site specificity and seasonality of AVM and the onset and duration of exposure. We accomplished these objectives with the use of sentinel birds, both wild-caught coots and game-farm mallards, that were released on a lake (Lake Surf, North Carolina) where recurrent outbreaks of AVM had been documented.

## MATERIALS AND METHODS

### Study area

Lake Surf (35°14'N, 78°12'W; also known as Woodlake; Fig. 1), near Vass, North Carolina, was selected for study because AVM has been documented in coots at that site every year since 1997 (National Wildlife Health Center [NWHC], unpubl. data). Lake Surf is a 456-ha impoundment created in 1973. Land cover prior to impoundment was forested wetlands, and

the current shoreline consists of residential homes, golf courses, a dam, and pine forests. Crane Creek, Little Crane Creek, Beaver Creek, and Cypress Creek drain to Lake Surf. The dominant cover types in the drainage basin are upland pine forests, pastures (primarily horse farms), row crops, (primarily tobacco and vegetables), and forested wetlands. The dominant submerged vegetation in the lake is hydrilla (*Hydrilla verticillata*). No chemical control of hydrilla has been attempted since 1993, but liquid copper, copper sulfate, diquat dibromide, glyphosate, and 2, 4-dichlorophenoxyacetic acid (2,4-D) were all used at the site in the late 1980s and early 1990s to control this plant. Migrating coots typically arrive at Lake Surf and other lakes in the vicinity in September or October and stay through March or April.

Three lakes were used as control sites during the course of the study (Fig. 1), including Crystal Lake in 1999 and Harris and Trace Lakes in 2000–01. Crystal Lake (35°14'N, 79°19'W) is a 32-ha impoundment of Mill Creek near its confluence with the Little River in Moore County, North Carolina. It was impounded in the 1830s to serve a now defunct grist mill. Dominant aquatic vegetation is water milfoil (*Myriophyllum* sp.) and hydrilla. Major land uses in the watershed include golf courses, forestry, and agriculture. Harris Lake (35°36'N, 79°57'W) is a 1675-ha impoundment of Buckhorn Creek in Wake and Chatham Counties, North Carolina. Although the lake was created and used as a cooling water source for a nuclear power plant in 1983, it is very similar to Lake Surf in age, bird use, aquatic vegetation, and other features. Harris Lake is also used extensively for recreation and research, and land use in this watershed consists primarily of forestry and agriculture. At least 55 species of aquatic macrophytes have been identified in the lake, but the dominant species is hydrilla. Trace Lake (35°25'N, 79°06'W) is a 141-ha impoundment of the Upper Little River in Lee County, North Carolina. It was impounded in the early 1970s and is the focal point of a golf course and residential development. The dominant aquatic vegetation is hydrilla.

### Sentinel birds

In 1998 and 1999, apparently normal wild coots were captured using a hand-held net from a boat while nightlighting at Tennessee National Wildlife Refuge (Paris, Tennessee, USA) and Lake Monona (Madison, Wisconsin, USA). A subsample from each group (four to five birds) was euthanized by cervical dislocation and their brains collected and examined

TABLE 1. Date and location of North Carolina where sentinel coots and mallards were released and the number of avian vacuolar myelinopathy (AVM) positive cases in birds that were recovered, either by recapture or that were found sick or dead.

Release date	Location	No. coots released	No. mallards released	AVM positive/ number recovered
20 December 1998	Lake Surf	54		1/3
18 December 1999	Lake Surf	26		8/10
	Lake Surf		40	4/20
	Crystal Lake		20	0/13
31 July 2000	Lake Surf		94	2/65 <sup>a</sup>
	Harris Lake		28	0/14
8 November 2000	Lake Surf		116	25/46
	Trace Lake		39	0/26
5 January 2001	Lake Surf		39	0/13

<sup>a</sup> The two sentinel mallards with AVM lesions were found sick in December 2000.

histologically to confirm the absence of AVM in the group. In 1999 and 2000, hatch year game-farm mallards ( $\geq 4$  mo old) were purchased from Whistling Wings (Hanover, Illinois, USA) and Abendroth's (Waterloo, Wisconsin), and subsamples (nine and five birds, respectively) were likewise euthanized and their brains examined for evidence of AVM. All birds were wing clipped, and numbered leg bands and pagtagal tags were applied to identify individuals.

#### Study design

Sentinel coots and mallards were transported to Lake Surf and released there or in nearby control lakes (Table 1). The first year of the study (1998) was considered a pilot study, and only coots were released (Table 1). In 1999, game-farm mallards were used in addition to coots, as they were much easier to obtain and also easier to monitor and re-capture in the field. During these first 2 yr of the study, sentinel birds were observed periodically by boat or from shore, and sick and dead sentinel birds were recovered whenever they were observed and could be caught. Sick and dead wild birds were collected opportunistically. Sick birds were euthanized by cervical dislocation, and brains were collected from these and dead birds and immediately placed in 10% buffered formalin for histologic examination. In February and March, attempts were made to recapture all surviving sentinels that could be found using swim-in traps or by nightlighting. These birds were euthanized and their brains were collected for histologic examination.

During the 2000–01 season, only game-farm mallards were used as sentinels and a more intensive study was conducted. That season, sentinel birds were released on Lake Surf at three different times: late July ( $n=94$ ), early Novem-

ber ( $n=116$ ), and early January ( $n=39$ ). Each time the birds were released at three different locations (Fig. 1) and fed cracked corn periodically at the release sites to encourage them to establish some site fidelity. Sentinel birds were then observed and counted nearly every day. They were recaptured periodically by boat, by hand, or with swim-in traps, and a subsample (10–20) was euthanized by cervical dislocation to collect brains for histologic examination. Whenever possible, sick sentinel birds were captured and euthanized and brains from these and all dead birds found were immediately placed in 10% buffered formalin for histologic examination. A group of 35 domestic geese foraging on littoral vegetation and golf courses adjacent to the lake were also captured and euthanized in the summer of 2000; brains were collected from 24 for histologic examination. As in the previous years, sick and dead wild birds were collected and examined opportunistically. Initially in 2000, Harris Lake was used as a control lake and 20 birds were released there in 31 July, however since waterfowl hunting is allowed on this lake in the fall, another nearby lake, Trace Lake, was used as a control site for the fall release of 39 sentinel mallards. In late February, at the end of the study period, attempts were made to recapture all surviving sentinels at Lake Surf and Trace Lake using swim-in traps; they were euthanized and their brains were collected for histologic examination.

#### Histology

Formalin-fixed brain tissue was routinely processed for paraffin embedment, sectioned at 5  $\mu\text{m}$ , and stained with hematoxylin and eosin. White matter in four regions of each brain was examined by light microscopy: optic tectum,

optic chiasm, brainstem, and cerebellar folia. A bird was considered positive if diffuse white matter vacuolation was present in the optic tectum and at least one other region. The extent of the lesions were described as mild, moderate, severe, or marked.

Formalin-fixed optic tectum from one sentinel coot and one sentinel mallard that had lesions of AVM by light microscopy were processed for examination by transmission electron microscopy. These tissues were stored in 0.1 M phosphate buffer, postfixed in 1% osmium tetroxide, stained with 2% uranyl acetate, and embedded in Epon Araldite. Semithin 1  $\mu$ m sections were stained by toluidine blue and used to evaluate tissue orientation by light microscopy. Ultrathin sections were stained with lead citrate and examined using a Philips 410 transmission electron microscope. Sections were assessed for the presence of intramyelinic vacuoles associated with separation of myelin lamellae at the intraperiodic line, a characteristic lesion of AVM.

### RESULTS

Brains from the subsample of five coots from Tennessee and four coots from Wisconsin that were euthanized upon capture were normal on microscopic examination. Likewise, the 14 game-farm mallards euthanized and examined upon purchase were negative for brain lesions associated with AVM. Based on these results, it was assumed that the sentinels were AVM-free upon release.

In 1998, sick wild coots were observed at Lake Surf as early as 23 October, and the disease was confirmed in a wild coot and a wild mallard found dead at this location on 6 November. Of the 54 sentinel coots released on Lake Surf on 20 December 1998, only three were recovered, all on day 5 post-release (Table 1). Two were found dead and histologic examination of their brains was inconclusive. The third bird was found sick with neurologic signs (severe motor impairment) and was easily captured; it was held for 3 days and then euthanized just prior to shipment to NWHC. Histologic examination of its brain revealed moderate vacuolar myelinopathy. Despite several attempts, efforts to locate the remaining sentinel coots failed.

In 1999, one wild coot found dead at Lake Surf on 10 November was diagnosed with AVM, and 14 sick or dead wild coots picked up in late December and early January were also confirmed with the disease. Twenty-six sentinel coots were released on Lake Surf on 18 December 1999 (Table 1). Thirteen days post-release, a moribund sentinel coot was captured and euthanized and another was found dead on day 17. Both of these coots were diagnosed with AVM. Electron microscopic examination of the brain from one coot confirmed the diagnosis. In March of 2000, 75 days after placement in the field, eight of the remaining sentinel coots were captured and euthanized. Although all of these birds appeared healthy, five of the eight were found to have mild to moderate brain lesions associated with AVM. The remaining 16 birds were not recovered.

Forty sentinel mallards were also released on Lake Surf on 18 December 1999 (Table 1). On days 17 and 19 post-release, three mallards were captured and euthanized. These birds showed no neurologic signs but were emaciated and lethargic. All three of these birds, plus another sentinel mallard found dead on day 20, were diagnosed with AVM, with moderate to marked lesions. Electron microscopic examination of the brain from one mallard confirmed the diagnosis. Sixteen of the remaining sentinel birds were recaptured in March 2000, on day 75 post-release; none of these had brain lesions suggestive of AVM. The remaining 20 sentinel mallards were not recovered. Twenty sentinel mallards were also released on a control lake, Crystal Lake, on 18 December 1999. No signs of illness were ever observed in any of these sentinel birds and all were accounted for until day 75 when 13 were ultimately recaptured and euthanized; none had brain lesions suggestive of AVM. The remaining seven sentinels were not recaptured.

Ninety-four sentinel mallards were released on Lake Surf in late July 2000 (Table 1). During August, September, and

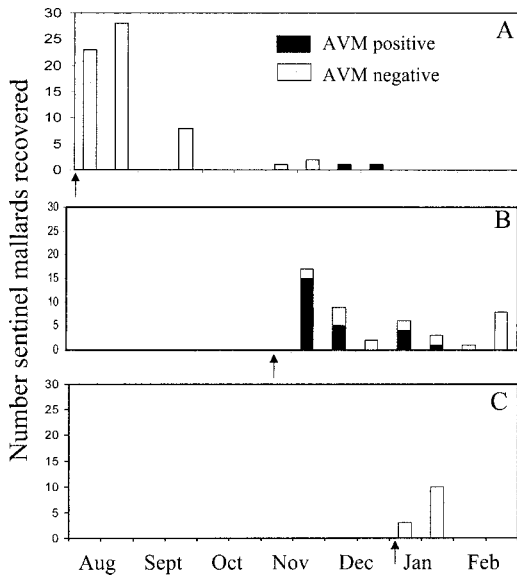


FIGURE 2. Number of sentinel mallards released at Lake Surf, North Carolina and recovered, either by capture or that were found sick or dead, and their disease status [positive or negative for avian vacuolar myelinopathy (AVM)] over 2 wk periods, August 2000–February 2001. Arrows indicate release dates of A) 94 birds on 31 July 2000, B) 116 birds on 8 November 2000, and C) 39 birds on 5 January 2001.

October, no sick birds, either sentinel mallards or wild birds, were observed on Lake Surf. Sixty-three apparently healthy sentinel mallards were recaptured prior to December 2000 and euthanized to collect brains for histologic examination (Fig. 2). None had brain lesions associated with AVM. Neither did the 24 domestic geese captured at Lake Surf during August 2000. However, two sentinel mallards released with the group in July were found sick on December 13, and lesions of AVM were detected in their brains. Of the 28 sentinel birds released on the control lake, Harris Lake, and monitored during July through September 2000, 14 were recaptured and examined for brain lesions; all were negative.

Another group of 116 mallards were released at Lake Surf in early November 2000 (Table 1). Of these, 46 were recovered between mid-November and late February and 25 (54%) were positive for

AVM by histologic examination (Fig. 2). Two of four sentinel mallards that were captured 6 days post-release and showed no evident clinical signs of disease had mild brain lesions indicative of AVM. Thirteen birds found either sick or dead in mid-November, 7–12 days after placement in the field, were all diagnosed with AVM. The sick birds showed signs of motor impairment, including an inability to right themselves and abnormal swimming posture. Several hundred wild birds were observed sick or dead during this same time period in November, and 38 wild coots and two wild mallards were likewise diagnosed with AVM. An additional two sentinel birds that were considered mildly sick and easily captured in December were also positive for AVM, and eight of 18 birds with no apparent signs recaptured in December and January were confirmed with mild to severe lesions of AVM. Nine sentinel birds recaptured in February were all negative. Most of the AVM positive sentinels came from two release sites (Fig. 1): the boat ramp (11 of 16 positive) and the dam (13 of 15 positive). At the third release site (Mallard Cove), only one bird was positive of 15 recovered. Of the 39 birds released at the control site, Trace Lake, on 8 November 2000, 26 were ultimately recaptured between November 2000 and February 2001, euthanized, and examined for AVM brain lesions; all were negative.

In early January 2001, an additional 39 birds were released on Lake Surf. Thirteen were recovered by the end of January, and none of these had brain lesions associated with AVM. Although several attempts were made to trap the remaining sentinel birds in February, they evaded capture when water levels in the lake dropped and the birds moved into residential areas surrounding Lake Surf which ruled out more aggressive means of recovery. This group of birds was observed regularly until the end of February when our study period ended, and no sick or dead birds were found.



## DISCUSSION

The repeated occurrence of AVM in sentinel coots and/or mallards within as little as 5–17 days after release on a lake with recurrent AVM outbreaks provides direct evidence that disease exposure is site-specific and related to local conditions in the lake. We contend that the causative agent of AVM is present at specific lakes (and possibly even specific locations in lakes), most likely at those sites where large numbers of clinically affected birds have been found. It is unlikely that migrating birds arrive at Lake Surf with the disease, but rather they acquire it there. Although it may be possible for AVM exposed birds to move from one lake to another, no sick birds or birds with AVM lesions have been detected in nearby lakes with similar populations of birds. Also, it is apparent that the time between exposure and the onset of disease signs or death can be relatively rapid. In 1998, one sentinel coot became sick with AVM within 5 days post-release, and in 2000, one sentinel mallard was found dead from AVM within 7 days post-release. In addition, two of four apparently healthy mallards recaptured 6 days post-release in November 2000 were found to have brain lesions, although they were not exhibiting obvious neurologic signs. Even slight impairment might hinder bird movement, but certainly more work is needed to clarify the clinical and behavioral effects of AVM in migratory birds. Placement of radio-tracking devices on wild birds in lakes with AVM outbreaks would be a useful approach to evaluate the progression of clinical signs in exposed birds and their movement between lakes.

The findings of our study also demonstrate the seasonality of exposure and occurrence of AVM. Sentinel mallards released in late July 2000 and sampled periodically through the end of October did not develop signs of disease or brain lesions; whereas numerous mallards released in early November 2000 contracted the disease and became sick or died within

7–12 days post-release. Brain lesions were also detected in re-captured birds from this group as long as 2 mo post-release (in late January), although no clinical signs were evident in these birds at the time of capture. Sentinel mallards released at Lake Surf in early January 2001 at the same sites and recaptured up to 3 wk later did not contract the disease. These findings suggest that the causative agent of AVM may persist in the lake and be available to birds for up to several months but is not present year-round at levels requisite to induce disease. Other observations corroborate this finding. In 1998, wild coots with neurologic signs were observed on Lake Surf as early as 23 October, and nearly 2 mo later, a sentinel coot released in the lake in December and found sick 5 days later was confirmed to have contracted the disease. In 1999, wild birds found dead on 8 November were confirmed with the disease, and several sentinel birds, both coots and mallards, released in December were diagnosed with AVM approximately 13–17 days later.

In general, the severity of clinical signs does not appear to be closely linked with the severity of the brain lesion, as coots and mallards with no detectable signs had lesions described as severe or marked and several birds with obvious and even severe neurologic impairment had brain lesions described as mild or moderate. However, a more rigorous examination of birds with a known duration of exposure is required to fully address this question. It is apparent that the brain lesion could be found in coots with no detectable signs of illness for several months after the initial outbreak was detected and clinically ill birds were present. In the 1999–2000 season, sentinel coots with no detectable clinical signs that were recaptured in March 2000, 75 days post-release, had brain lesions, although no sick birds had been observed since January. In a related study, Larsen et al. (2002), discovered that affected coots captured at Lake Surf and brought into cap-

tivity still had brain lesions of AVM as long as 65 days post-capture.

Interestingly, unlike the sentinel coots, none of the sentinel mallards recaptured on Lake Surf in March 2000 had AVM lesions. The reason for this is unknown, but it is possible that coots were more susceptible or sensitive to the causative agent than mallards or their feeding habits made them more likely to encounter the agent. Alternatively, it is possible that game farm mallards with AVM were less capable of recovering from the disease or evading capture by predators, and, thus, did not survive as long as affected coots. Even so, as in previous studies on lead poisoning (Rocke et al., 1997) and avian botulism (Rocke and Brand, 1994), game farm mallards proved to be effective sentinels for studying the epizootiology of AVM. Sentinel mallards adapted readily to the lakes where they were released and foraged naturally. The onset of disease in sentinel mallards coincided very well with the onset of disease in wild coots and waterfowl at Lake Surf. Furthermore, sentinel mallards established some fidelity to or near their original release site and were very easy to observe and recapture, unlike sentinel coots, which dispersed throughout the lake and became very adept at evading observation and capture. Establishing a group of sentinel mallards at specific sites in the lake allows investigators to narrow their environmental sampling efforts to sites where the disease is confirmed.

Until the source and causative agent of AVM are discovered, the significance of the disease and potential management implications remain unknown. Since 1994, at least 80 bald eagles deaths have been attributed to AVM (NWHC, unpubl. data), although the actual number is probably much higher. Dense vegetation and the size of some sites hampered monitoring and surveillance efforts. The number of coots affected by AVM over the years is

unknown, but is probably in the thousands. So far, only a small number of wild waterfowl are known to have died from this disease. Our findings that exposure is site-specific, disease onset is rapid, and the agent may persist in the environment for only a few months at a level sufficient to induce disease in birds further supports the hypothesis that the cause of AVM is a chemical substance, most likely of natural origin (viz., a toxin), and this knowledge will help focus the search for its identity.

#### ACKNOWLEDGMENTS

The authors wish to thank the management and residents of Woodlake Country Club, Crystal Lake, Harris Lake, and Trace Lake for access to each lake and assistance with the project. We also are grateful to the North Carolina Wildlife Resources Commission and USGS Water Resources Division for loan of equipment and the Tennessee National Wildlife Refuge for assistance in trapping coots. The technical assistance of J. Bayerl, D. Berndt, S. Campbell, T. Creekmore, E. Galban, S. Hansen, A. Schrader, and S. Smith was much appreciated as were the editorial comments provided by J. C. Franson. Funding was provided, in part, by the U.S. Fish and Wildlife Service's Division of Environmental Contaminants (study identifier 200040002.1).

#### LITERATURE CITED

- LARSEN, R. S., F. B. NUTTER, T. AUGSPURGER, T. E. ROCKE, L. TOMLINSON, N. THOMAS, AND M. K. STOSKOPF. 2002. Clinical characterization of avian vacuolar myelinopathy in affected American coots. *Journal of American Veterinary Medical Association*. In press.
- ROCKE, T. E., C. J. BRAND, AND J. G. MENSİK. 1997. Site-specific lead exposure from lead pellet ingestion in sentinel mallards. *Journal of Wildlife Management* 61: 228-234.
- , AND ———. 1994. Use of sentinel mallards for epizootiologic studies of avian botulism. *Journal of Wildlife Diseases* 30: 514-522.
- THOMAS, N. J., C. U. METEYER, AND L. SILEO. 1998. Epizootic vacuolar myelinopathy of the central nervous system of bald eagles (*Haliaeetus leucocephalus*) and American coots (*Fulica americana*). *Veterinary Pathology* 35: 479-487.

Received for publication 20 December 2001.